

HOMEOCARE

आरोग्य

BE HEALTHY, BE HAPPY.

A HAPPY
COUPLE
STORY

CANCER &
HOMEOPATHY

RENAL
CALCULI
PERMANENT
TREATMENT

Dr. Samuel Hahnemann

259th

BIRTH ANNIVERSARY
SPECIAL EDITION



HOMEOCARE
INTERNATIONAL

Pvt Ltd

LEADERS IN WORLD-CLASS HOMEOPATHY

An ISO 9001-2008 Certified Clinic with German Accreditation



Dr Rohit Morlawar

Editor's Note

" Hello, I welcome You with so much sincere happiness to our Magazine"

HOMEOCARE
arogyā
 Be Healthy, Be Happy.

In an ever Changing time but an "exciting" one, we promise you to bring very informative and thought provoking content and true stories of cured chronic cases at Homeocare Clinics.

At this time, I would like to take a moment to thank our entire staff for their hard work and dedication. I would especially like to thank all the Doctors- who contributed to the magazine, and for extending their full support. Please feel free to contact me with any spectacular projects that we may profile in a future issue of the magazine "continue to thrive and see you next month".

Dr Rohit Morlawar
 Editor-in-cheif

As a tribute to Dr Samuel Hahnemann, Father of Homeopathy his birthday – 10th April is celebrated as World Homeopathy Day. On this occasion we feel previlaged to dedicate all the wonderful cures and gentle treatments published in this Volume 1 of Homeocare Arogya magazine to Hahnaemann, the master who sacrificed his life and career, experienced lots of opposition and criticism with lot of courage combined with intelligence and dedication to lay string scientific foundations to advanced medical system – Homeopathy.

Let the gentleness and greatness of this healing science spread and flourish

Let the Almighty bless all of us.

Medical Audit Team.

Co Editors :
 Medical Audit Team

Chief Advisor:
 Dr. Sudheer Reddy

Contributors :
 Dr. Praveen Kumar Bhirde
 Dr. Ramadas
 Dr. Ratna Babu
 Dr. Anil Kumar
 Dr. Venkat Narayana

Design Consultant :
 Raj Kumar VT



Chairman's MESSAGE

Greetings on the occasion of
World Homeopathy Day.

As Human Existence is challenged by incomprehensible diseases and ailments which are ever growing and are becoming difficult to cure. Treating these diseases effectively and permanently without any side effects is the need of the hour, this laid foundations for establishment of world class Homeopathic clinics under the banner of Homeocare International. To spread the gentleness and efficacy of

quality Homeopathy, and to cure the innumerable chronic disease is the motto of Homeocare International.

With an aim to provide highest quality health-care services to the patients, we have integrated and brought together traditional forms of Homeopathy with State-of-art infrastructure, cutting Edge technology, highly integrated and comprehensive information systems which helped us to set newer bench marks by achieving highly effective therapies in Homeopathy for many Chronic and incurable diseases.

We made our modest beginning and right from the initial days we were driven by passion to create new benchmarks in health care, supported by most enthusiastic, sincere, diligent doctors and support staff to attain success. Today Homeocare International is a chain of 28 clinics spread across South India and is backed by 300 highly qualified Doctors and more than 500 well trained support staff. I thank the entire team who believed in my dreams, vision and made us cure lakhs of patients with empathy & compassion. We keep moving forward, our motto keeps us leading new paths, this month we opened our doors in the historical city of Mysore and added an additional branch in the city of chennai. we are aspiring to expand fast to other parts of the world.

I appreciate the continuous efforts of Dr Rohit in bringing out our in-house magazine Homeocare Arogya in a very short span of time inspite of a very busy schedule.

With Regards,
Dr Srikant Morlawar,
CMD,
Homeocare International Pvt. Ltd.

A Happy Couple Story :



This is a true story of a couple with infertility since 20 years and conceived with Homeopathy treatment at Homeocare International.

There may be many causes for infertility but Homeocare International offers one stop solution for all your infertility problems, to make a complete and Happy Family.

Case of : Dr Praveen Kumar Bhirdi

A letter from one of our patrons from karnataka



HOMEOCARE INTERNATIONAL
 Leaders in world-class homeopathy
 www.homeocare.in
 24/10/2010

ವಾಸು ಶ್ರೀ ಸುನಂದಿ ಹಿಂಪುಸ್ತಿ 40 ಹೆಚ್ಚಿ -
 ದ್ರ. ಡಿ. ಎಂ. ಹೇ. 54 ವಾಸು ಹಿಂಪುಸ್ತಿಗೆ 20 ವರ್ಷದಿಂದ
 ಇವರ ವಾಸು ಹಿಂಪುಸ್ತಿಗೆ 20 ವರ್ಷದಿಂದ ಇವರ ವಾಸು ಹಿಂಪುಸ್ತಿಗೆ
 - ವಾಸು ಹಿಂಪುಸ್ತಿಗೆ 20 ವರ್ಷದಿಂದ ಇವರ ವಾಸು ಹಿಂಪುಸ್ತಿಗೆ
 ರೋಗದ ಅರಿವು ಹಿಂಪುಸ್ತಿಗೆ 20 ವರ್ಷದಿಂದ ಇವರ ವಾಸು ಹಿಂಪುಸ್ತಿಗೆ
 ಮಿತ್ರಿಯು ಹಿಂಪುಸ್ತಿಗೆ 20 ವರ್ಷದಿಂದ ಇವರ ವಾಸು ಹಿಂಪುಸ್ತಿಗೆ
 ಬಹಳಷ್ಟು ವಾಸು ಹಿಂಪುಸ್ತಿಗೆ 20 ವರ್ಷದಿಂದ ಇವರ ವಾಸು ಹಿಂಪುಸ್ತಿಗೆ
 (ಹಿಂಪುಸ್ತಿಗೆ 20 ವರ್ಷದಿಂದ ಇವರ ವಾಸು ಹಿಂಪುಸ್ತಿಗೆ
 ಬಹಳಷ್ಟು ವಾಸು ಹಿಂಪುಸ್ತಿಗೆ 20 ವರ್ಷದಿಂದ ಇವರ ವಾಸು ಹಿಂಪುಸ್ತಿಗೆ

ಇಂಟರ್ ನೆಟ್ ಸಂಪರ್ಕಿಸಿ
 x ವಾಸು ಹಿಂಪುಸ್ತಿ

we are there for you, always... ALWAYS

registered office :
 # 67, # 1st colony, s p road, secunderabad - 500 003, ap india

helpline : 09 00 - 20 00 hrs

hyderabad :
 begumpet : +91-40-3248 4545 / 8632 1155
 abids : +91-40-6673 1155 / 6454 4949
 jubilee hills : +91-40-2354 0327 / 6451 3050
 kukatpally : +91-40-2305 7631 / 69952566
 vijayawada - 0866 - 2493755 / 2495111
 vishakhapatnam : 024 7901111
 tirupati : 224 7000111

bangalore
 jayanagar : +91-80-6548 4195 / 22448100
 malleshwaram : +91-80-6583 4877 / 23448067
 www.homeocare.in

ಪಾಟೀಲ್ ನರ್ಸಿಂಗ್ ಹೋಮ್ & ಸ್ಪ್ಯಾನಿಂಗ್ ಸೆಂಟರ್.
 ಔ. ಅನ್ವತೆ : 270765 ಮನೆ : 230808

ಶಸ್ತ್ರಚಿಕಿತ್ಸಾಲಯ, ಅಲ್ಪಾಸೌಂದ ಸ್ಪ್ಯಾನಿಂಗ್ ಮತ್ತು ಪ್ರಸೂತಿ ಗೃಹ
 ಬಸ್-ಸ್ಪಾಂಡ್ ರೋಡ್, ಗಂಗಾವತಿ - 583 227. *Due = 100kg*

Dr. V. A. PATIL M.S. FAIS.
GEN SURGEON



ಡಾ|| ವಿರುಪಾಕ್ಷ ಪಾಟೀಲ್ ಎಂ.ಎಸ್. ಎಫ್.ಎಫ್.ಎಸ್.
 ಅಪ್ಪಣ್ಣಂಗ್ ಸರ್ಜನ್, ಶಸ್ತ್ರಚಿಕಿತ್ಸಕರು ಹಾಗೂ ಸೋರೋಲಜಿಸ್ಟ್

Dr. (Smt.) S.V. PATIL M.D.
GYNAECOLOGIST

ಡಾ|| ತ್ರೀಮತಿ ಸಂಗಮ್ ಪಾಟೀಲ್ ಎಂ.ಡಿ.
 ಅಪ್ಪಣ್ಣಂಗ್ ಗೈನೇಕೋಲೋಜಿಸ್ಟ್ ಸ್ತ್ರೀರೋಗಚಿಕಿತ್ಸಕರು ಮತ್ತು ಸೋರೋಲಜಿಸ್ಟ್

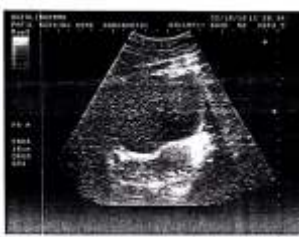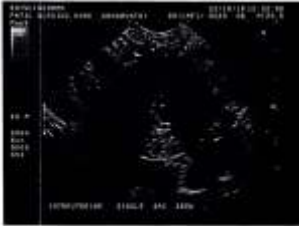
ಸಂದರ್ಶನ ಸಮಯ: ಬೆಳಿಗ್ಗೆ 10 ರಿಂದ 3 ರವರೆಗೆ ಸಾಯಂಕಾಲ 6 ರಿಂದ ರಾತ್ರಿ 9 ಗಂಟೆವರೆಗೆ. (ಪ್ರತಿ ರೋಗಿಯರ ಬುದ್ಧಿವಂತಿಕೆ ರನಂತರ ದೇ! ಇರುತ್ತದೆ)

L.M.P-7/9/2010	ಹೆಸರು	<i>Sr</i>
EDD-14/6/2011	Rx	ದಿನಾಂಕ ...22/11/2010
Wt 62Kg	H/o 1/2 weeks of preg-test of urine is +ve	
B.P-110/80	Intrauterine alive single sac is seen	
<u>Pain!</u>	Tab. Doxinate 0.1 (8)	
	Tab. Folimus 1 (8)	
	Combi Aristozyme	

ಯೋಗ್ಯ ಬೆಲೆಗೆ ಬಿಡದ ದೂರೆಯುಪ ಸ್ಥಳ : ಔ. ಅನ್ವತೆ : 270765

ಶ್ರೀ ಗಣೇಶ ಮೆಡಿಕಲ್ಸ್

ಪಾಟೀಲ್ ನರ್ಸಿಂಗ್ ಹೋಮ್ ಹತ್ತಿರ, ಬಸ್-ಸ್ಪಾಂಡ್ ರೋಡ್, ಗಂಗಾವತಿ - 583 227.



*Patient names hidden

Renal Calculi and permanent Solutions at Homeocare:

HOMEOCARE
arogyā
 Be Healthy, Be Happy.

This is an example of a case where Homeopathy can be used to avoid Surgery.

The reports before treatment shows multiple renal calculi in both kidneys and how Homeopathic treatment helped the patient to avoid surgery and cured him without a scar & help in further by trying & controlling that further no more stones are formed

This is the Gentleness of Homeopathy.

Case of : Dr Ratna Babu

Before

Patient Name *	Patient ID	:101374567/R
Sex / Age	Report Date/Time	:M/033Y :12-04-2013 13:31:42
Modality	Ref. Phys.	:CT :DR MALLIKARJUNA.C.

DEPARTMENT OF RADIOLOGY AND IMAGING SCIENCES CT SCAN OF ABDOMEN & PELVIS PLAIN

CT scan of abdomen & pelvis was performed without IV nonionic contrast on 128 slice multidetector - row CT scanner and images are reconstructed in axial, coronal and sagittal planes.

Liver is normal in contours and attenuation. No focal or diffuse lesion is seen. No evidence of intrahepatic biliary dilatation is seen.

Gall bladder is regular in contours and attenuation. No evidence of calculi.

Pancreas is normal in shape and contours. Peripancreatic planes appear normal. No evidence of calcification or pancreatic duct dilatation is seen.

Spleen is normal in contours and attenuation.

Both adrenals are normal.

Right kidney measures 9.8 x 4.4 cm, small calculi measuring 2 & 3 mm in size in the upper and midpole calyx.
 Left kidney measures 10.3 x 5.2 cm. Right ureter is normal.
 Left ureter is mildly dilated calculus measuring 8.3 mm in the left distal ureter causing mild obstruction of the lumen.
 Both kidneys are normal in size, shape and attenuation.

Stomach and bowel loops are normal.

Aorta and IVC are normal.

Urinary bladder is normal.

Prostate is normal.

Rectum and perirectal fat planes are normal.

No ascites / adenopathy.

IMPRESSION:

- * Right small renal calculi.
- * Left distal ureteric calculus with mild hydronephrosis.
- For clinical correlation.

Dr. Krishna Mohan
Sr. Consultant Radiologist

After

Patient Name *	Patient ID	:101421508/S
Sex / Age	Report Date/Time	:M / 33 Y :30-01-2014 10:28:32
Modality	Ref. Phys.	:CT :C.MALLIKARJUNA

DEPARTMENT OF RADIOLOGY AND IMAGING SCIENCES CT SCAN OF KUB (PLAIN)

CT scan of KUB was performed without I.V. contrast on 128 slice multidetector - row CT scanner and images are reconstructed in axial, coronal and sagittal planes.

Hx - Left flank pain.

Adrenals are normal.

Right kidney measures 9.9 x 4.4 cms.
 Normal in size, shape and attenuation.
 No calculi / hydronephrosis.

Left kidney measures 10.2 x 4.3 cms.
 Normal in size, shape and attenuation.
 No calculi / hydronephrosis.

Urinary bladder is normal.

No ascites.

No obvious lymphadenopathy.

Visualised sections of liver, spleen and pancreas appear normal.

Visualised sections of thorax reveals low attenuation / emphysema in medial basal segment of right lower lobe with focal calcification within.

Impression :

- * Negative study for urolithiasis.
- * No hydronephrosis bilaterally.
- * Visualised sections of thorax reveals low attenuation / emphysema in medial basal segment of right lower lobe with focal calcification within.

For clinical correlation.

Dr. Raghavendra. K. J
Consultant Radiologist



K.N. Srinivas

AC-14

Has Iam suffering with kidney stones (LFT kidney 8.3 X RT kidney 3.3 sizes) ALlopathi Doctor suggested me for operation Meen of the time I saw TV Advertisement and Came to Homeo Care International PVE Led Branch : Masab Tank at Masab Tank Branch Support Staff helped me and kept Appointment with Dr. RATNABABU / Dr. KRUPA SAGAR and they suggested me not to go for operation so I used HCI medicine and I was cured In 5 months without operation and I Really Thanks to HCI and Dr. RATNABABU / Dr. KRUPA SAGAR who cured my problem

Thanking you

K.N. Srinivas
9032143001

Registered Office : # 63, Sindi Colony, S.P. Road, Secunderabad - 500 003,
Andhra Pradesh, INDIA. Ph : 8885037219 / 9885747979 / 9849056637
www.homeocare.in

ANDHRA PRADESH
HYDERABAD
VEJAYAWADA
TIRUPATHI
VISAKHAPATNAM
RAJAHMUNDRY
GUNTUR
HANUMAKONDA

KARNATAKA
BENGALURU
HUBLI
MANGALORE
DAVANGERE
TAMILNADU
CHENNAI
COIMBATORE
MADHURAI

Stop Diabetes:-

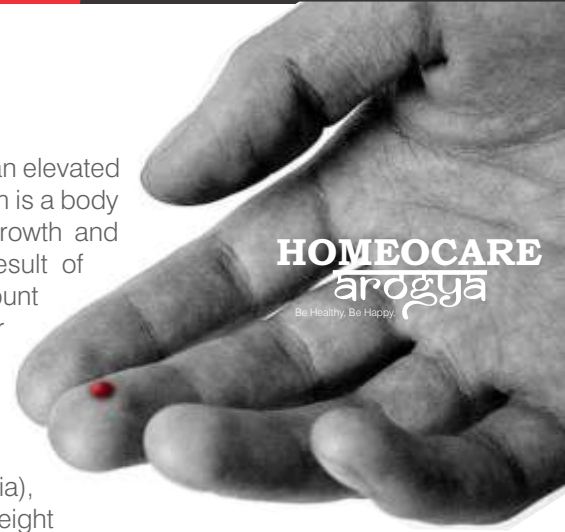Diabetes or Diabetes Mellitus is a condition in which there is an elevated glucose levels in the blood. It is type of metabolic disorder. Metabolism is a body mechanism on how our body uses digested food or energy for growth and development. In diabetes the metabolism fails. This may be a result of Pancreas defects, wherein insulin, the hormone that regulates the amount of glucose in the persons blood level is insufficiently secreted or decreased response of the body cells to the amount of insulin produced.

The symptoms of Diabetes are frequent urination(polyuria), increased thirst (polydipsia) and increased hunger (polyphagia), weight loss. The types of diabetes are :

Type1 Diabetes is a case in which the Pancreas are not able to produce insulin which results to lifetime dependency on insulin. It typically develops in children and young adults.

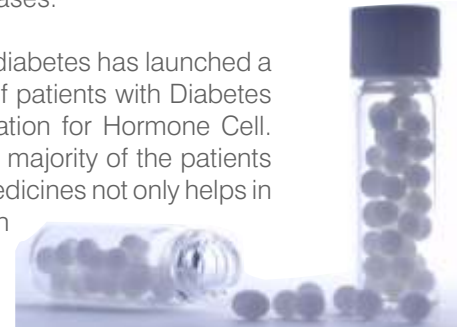Type 2 Diabetes is a case in which the cells in the body fail to react or use insulin what we call it as insulin resistance. It usually develops after 40 years, is also called as late onset Diabetes.

Gestational Diabetes, seen in pregnant women who have increased glucose level in their blood, and generally will subside after delivery.



Type 2 diabetes is becoming common and people who are obese and over weight are more prone to type 2 diabetes. Rapid change in the eating habits, increased availability of high calorie food, sedentary life style, increased consumption of fast foods are considered to be the main reasons for raise in people suffering from Diabetes. India is becoming the diabetic capital of the world, consumption of high carbohydrates and staple food being wheat or rice is predisposing Indians to diabetes, rapid change in life style and decreased physical activity with increased mental activity is also triggering Diabetes. Stopping diabetes is very important as untreated or uncontrolled diabetes can lead to complications which are lethal or will effect your quality of life. Cardiologist consider having Diabetes equals having an history of heart disease, as Diabetics are more prone to cardiovascular Diseases.

Homeocare International with the aim to help people suffering from diabetes has launched a specialised, unique Hormone cell. Vast experience of treating thousands of patients with Diabetes combined with Constitutional homeopathy treatment method is the foundation for Hormone Cell. Patient feed back after Homeopathy treatment at Homeocare suggest that majority of the patients experienced considerable improvement in their Quality of life. Homeopathy medicines not only helps in controlling the blood sugar levels but also corrects the root cause and helps in preventing or prolonging the complications of Diabetes. Prevention is better than cure, so we at Homeocare aim to prevent all the complications associated with Diabetes. Studies suggest that Homeopathy can cure stress induced Diabetes. So it is highly recommended for every diabetic Patient to Keep there Blood sugar level under control and to try Homeopathy to prevent and to enjoy the long term benefits of Homeopathy Treatment, by Preventing Complications



We found solution to keep
DIABETES under control



- Diabetic Foot
- Kidney Problems
- Peripheral Neuropathy
- Sexual Problems

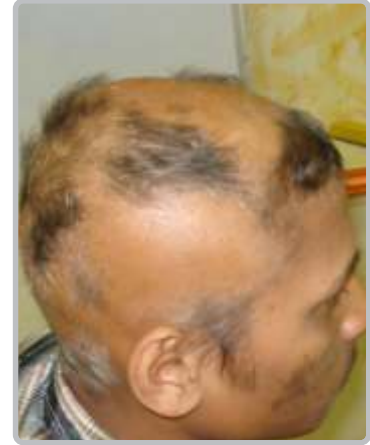Homeocare Solution for Auto Immune Diseases

HOMEOCARE
आरोग्य
 Be Healthy, Be Happy.

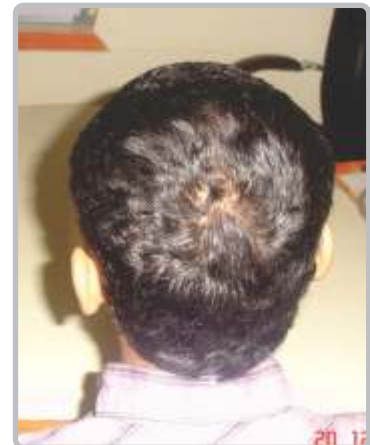A Case of Alopecia Universalis:

Picture show Patient During 2nd month of treatment. Pictures below are taken after 8 months of treatment

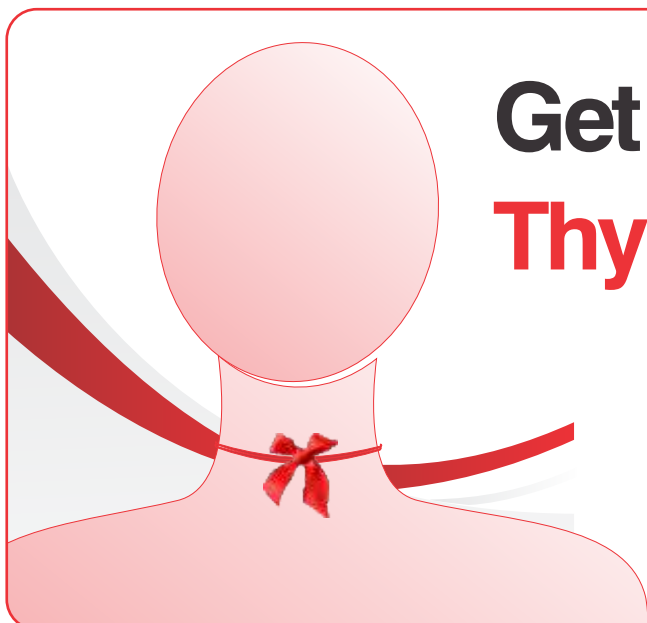Before:



After:



Case of: Dr. Anil Kumar



Get Rid of **Thyroid** Problems

- Hypothyroid
- Hyperthyroid
- Goitre

A case of slender Uterus

HOMEOCARE
arogyā
 Be Healthy, Be Happy.

This Reports make you rethink your opinion of Homeopathy and shows the efficacy of homeopathy in hopeless cases and stands as the only hope.

A young girl presented with Amenorrhoea and slender uterus. USG abdomen before treatment show the size of uterus and thickness of endometrium suggestive of slender uterus.

After 10 months of treatment the reports show a normal Uterus.

Case of : :Dr Ramadas.

Before

Patient Name	* [REDACTED] R/O KARIMNAGAR	Age	16 Y	Sex	F
Ref. Dr.	DR.P.SUNITHA.M.D.D.G.O.,	Date	30/06/11		

ULTRASOUND ABDOMEN

Liver: Normal in size and echotexture. No focal lesions/altered echotexture. NO IHBD

GB: Normal in size. Wall thickness is normal. No calculi / peri cholecystic collection.

Pancreas: Normal in size and echotexture. No focal lesions/altered echotexture

Spleen: Normal in size and echotexture. No focal lesions/altered echotexture

Aorta and IVC: Normal in course and calibre. No lymphadenopathy noted.

Both kidneys are normal in size and echotexture. Corticomedullary differentiation is maintained. No calculi / Hydronephrosis

Urinary Bladder: Partially filled. No calculi / mass lesions. No internal echoes.

Uterus: It is slightly slender measuring 66x38x23mm. Normal in echotexture. No focal lesions/altered echotexture. Endometrial echo measures 2mm.

Rt Ovary} It measures 25x18mm.

Lt Ovary} It measures 31x17mm.

Both ovaries are normal in size and echotexture.

No free fluid noted in abdomen.

IMPRESSION: * SLIGHTLY SLENDER UTERUS.

* ENDOMETRIAL ECHO MEASURES 2MM.


 DR. T. VAMSI MOHAN
 Radiologist.

After

Patient Name * [REDACTED] R/O KARIMNAGAR Age 16 Y Sex [REDACTED]
Ref. Dr. DR.P.SUNITHA.M.D.D.G.O., Date 20/04/12

ULTRASOUND ABDOMEN

Liver: Normal in size and echotexture. No focal lesions/altered echotexture. NO IHBD

GB: Normal in size. Wall thickness is normal. No calculi / peri cholecystic collection.

Pancreas: Normal in size and echotexture. No focal lesions/altered echotexture

Spleen: Normal in size and echotexture. No focal lesions/altered echotexture

Aorta and IVC: Normal in course and calibre. No lymphadenopathy noted.

Both kidneys are normal in size and echotexture. Corticomedullary differentiation is maintained. No calculi / hydronephrosis.

Urinary Bladder: Partially filled. No calculi / mass lesions. No internal echoes.

Uterus: It measures 71x44x33mm. Normal in size and echotexture. No focal lesions/altered echotexture. Endometrial echo measures 6mm and is normal.

Rt Ovary} It measures 31x30mm.

Lt Ovary} It measures 32x22mm. Both ovaries are normal in size and echotexture.

No free fluid noted in abdomen.

IMPRESSION: * NO SONOGRAPHIC ABNORMALITY NOTED.


DR. T.VAMSHI MOHAN
Radiologist.

Cancer & Homeopathy

This is a case of CA Stomach with metastasis and Diabetes Mellitus . The reports before treatment shows the size and location of the lesions. During treatment patient improved symptomatically, reports shows significant regression in size of primary and metastatic lesions.

Before

NAME : * PATIENT ID : 513004 AGE : 57 SEX : MALE
REF BY: Medicine M.R.D.No 389109
Scope Used : Pentax EG2870 K E.No :

UPPER GI ENDOSCOPY REPORT

Indication : Anemia for evaluation

Anaesthesia : Topical (Xylocaine viscous)

Esophagus : OG junction at 40cms - normal

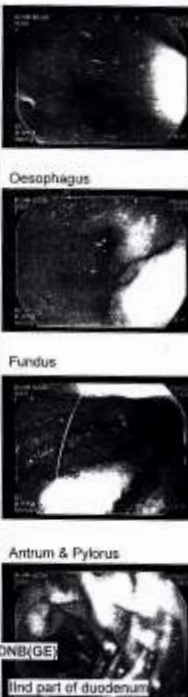
Stomach : Thickened ulcerated growth seen extending from GE junction upto the pyloric opening along the posterior wall with circumferential involvement of body at the places.No obvious gastric outlet obstruction seen. But mild narrowing of GE junction noted.Multiple biopsy taken.

Duodenum : Normal upto second part

IMPRESSION :
Growth in the stomach likely neo plastic.

Suggested : Biopsy taken (HPE report awaited)
Adv- CT scan abdomen and chest X ray.

08/10/2011 Dr.Abhijit Deshpande MD.,DNB(Med),DNB(GE)
Report Prepared By: Mlx



USG REPORT

Name : * Sex : Male Hospital No : 00513004
Dept : Medicine Age : 57 MRD No : 389109
Ward : NSBC3201E Date : 07/10/2011 BHI No : IP1776287
Scan No : D970245

Abdomen and Pelvis Scan Report 07/10/11 11:42:39

Liver : Parachymal echoes are normal. No focal mass lesion. Intra hepatic biliary radicles are normal.

Gall Bladder : Mild diffuse wall thickening noted.

Spleen : Normal in size and texture.

Pancreas : Obscured by bowel gas.

Kidneys : Right kidney measures 9.0cm in long axis. Cortical echogenicity and parenchymal thickness are normal. No pelvicalyceal dilatation.
Left kidney reduced in size measures 7.2 x 3.8cm. Cortical echogenicity is mildly increased. No pelvicalyceal dilatation.

Urinary Bladder : Filled well. No calculi.

Prostate : Mildly enlarged.Measures 3.1 x 4.0 x 3.8cm.Volume : 26cc. Minimal free fluid in abdomen. Mild wall thickening noted in fundal and body region of stomach.

Impression
1.Mild diffuse gall bladder wall thickening.
2.Smaller left kidney with increased renal cortical echoes -? medical renal disease.
3.Mild prostatomegaly
4.Mild gastric wall thickening in fundus and body.
5.Minimal free fluid in abdomen.
=> Suggested CECT abdomen.

DR.P.JENIKAR.,DMRD.,
PB : Ganesan.
Dr.Y.MUKUNTHARAJAN, DMED

CT REPORT

Name : * Hospital No. : 00513004 Scan No : 5818/20/11
Age : 57 MRD No. : 389109 BHI No. : IP1777156
Sex : Male Ward : NSBC3206 Date : 08/10/2011
Ref. By : DR.P.K.M. Dept. : Medicine

PART SCANNED : ABDOMEN AND PELVIS
TECHNIQUE: Multislice helical sections taken with dome of diaphragm to pubic symphysis without and with IV and oral contrast.

OBSERVATIONS:

1. DIFFUSE GAS & IJC WALL THICKENING SEEN INVOLVING LESSER CURVATURE, FUNDUS AND ANTRAL REGION OF STOMACH.
2. MINIMAL PERIGASTRIC FAT STRANDING NOTED.
3. MULTIPLE LYMPHNODES SEEN IN PERIGASTRIC COELIAC, PARAAORTIC REGION LARGEST MEASURING 2 CM.
=> SUGGESTED UGI SCOPE FOR FURTHER EVALUATION.
4. GB SHOWS HIGH DENSITY BILE WITHIN - ? SLUDGE/
5. LEFT KIDNEY SHOWS SIZE REDUCTION AND NORMAL PELVICALYCEAL SYSTEM.
6. NO FOCAL LIVER LESIONS.
7. NO FREE FLUID IN ABDOMEN.
8. VISUALIZED LUNG FIELDS SHOWS MULTIPLE SCATTERED LUNG NODULES IN BOTH LUNG BASES ? METASTASIS.

DR.T.MUKUNTHARAJAN, SR. CONSULTANT/RD
DR. N. KARUNAKARAN, CONSULTANT
DR. R. GANESH, JR. CONSULTANT
Clinical correlation is necessary, as this modality of investigation has its own limitations.
PB :S.Jeba.

After

Dear Sir,

Good morning. I am Age 57.
 was admitted with cough with expectorations for 2 months, loss of appetite, loss of weight, vomiting immediately after taking food for 2 months. I had a carcinoma stomach with diabetic mellitus. Now I have no vomiting, cough. My carcinoma symptoms are slowly decreasing. I feel better with gaining weight and with good appetite.

Thank you Sir

T.B. Arif
 I.D. No. AG-16.
 30.1.12.

Name: Age: 57 Sex: M ED. No: 01 / 3327

Ref. By: DR. T.N. KUPPUSAMI, MRBS, DMRT, DATE: 20-01-2012

CT REPORT: CHEST / ABDOMEN / PELVIS - PLAIN AND CONTRAST

TECHNIQUE:-

Multislice spiral CT volume scan of thorax / abdomen / pelvis were studied before and after oral and IV contrast.

Status :- A known case of Ca stomach (Adeno Carcinoma). Completed three cycles of chemotherapy. For follow up scan to assess the present status.

OBSERVATION:-

The present study shows significant regression of growth involving body of stomach measuring 5.6 x 1.8 cms (approx).

Reduction in size of peritoneal seedlings and multiple nodules noted.

There is evidence of reduction in size of peri pancreatic lymphnodal metastasis noted measuring 0.91 x 0.86 cms (approx).

No evidence of lung / mediastinal secondaries.

Trachea is centrally placed with normal lumen and wall. The mainstem and segmental bronchi are normal.

Both lungs show normal broncho vascular distribution and acinar pattern. No obvious focal mass seen.

Ascending, arch, descending aorta and its branches, main pulmonary artery and its major branches, SVC and its tributaries show normal calibre and position.

Cardiac configuration is normal. No obvious mediastinal or hilar lymphadenopathy.

No evidence of pleural effusion on either side. Esophagus appears normal.

Abdomen:-

Liver is normal in size, shape and CT density. No evidence of focal mass lesion or intra hepatic biliary radicles dilatation made out.

Gall and extra-hepatic biliary radicles appear normal.

Both kidneys and Adrenals are normal in size, shape and position. No evidence of mass lesion seen.

No evidence of free fluid in peritoneal spaces.

Visualised sections of bony parts appear normal.

Bladder is partially opacified with contrast. No evidence of intraluminal filling defect. The perivesicular fat planes are preserved. The rest of the pelvic organs appear normal.

IMPRESSION:-

1. The present study shows significant regression of growth involving body of stomach measuring 5.6 x 1.8 cms (approx).
2. Reduction in size of peritoneal seedlings and multiple nodules noted.
3. There is evidence of reduction in size of peri pancreatic lymphnodal metastasis noted measuring 0.91 x 0.86 cms (approx).
4. No evidence of lung / mediastinal secondaries.

Above findings are suggestive of favourable response to therapy

ENCL: FILM
G

DR. K.G. SRINIVASAN, MD., RD.,
CONSULTANT RADIOLOGIST

Thank you for the courtesy of this referral.

For any clarification, please contact Doctor's direct phone numbers : 88421 18869, 2528281 & 2528282

Note: The imaging is done by world's most advanced Multislice spiral CT-Siemens Sensation 64-Slice CT technology

Case of Rheumatoid Arthritis :



This is an example of a case of RA which is Relived .
Homeocare International offers Permanent solutions for all Kinds of Arthritis . Homeopathic medicines not only help to relieve pain but the advanced Genetic constitutional Homeopathic method cures it by correcting the root cause and makes your life pain free.

Case of : : Dr Venkatnarayana

From
V. Sadasubrahmanya
MILANO, Italy

ID - FG-70
Δ RA.

Homeocare International
leaders in world-class homeopathy
www.homeocare.in

Ref: Dr. Sri. Venkatnarayana

నాకు 18 నెలల నుండి ముందుగా కు
మధ్య కింది స్థలమున కు అవకాశము
చాలా ముఖ్యమైనది.

HOMEOCARE

V. సదాశివయ్య
I.D. NO - FG-70.

Before

DEPARTMENT OF RHEUMATOLOGY
 NZAM'S INSTITUTE OF MEDICAL SCIENCES
 PANJAGUTTA, HYDERABAD-500 082

Name : *
 IP/OP : 80403825

Date : 10-04-08
 Age/Sex : 44 /female

Test	Value	Normal Range	Lab Tech
CRP	/	<6 mg/l	/
IgMRF	60	<40 IU/ml	<i>Ln</i>
ANA	/	<1.0	/
Anti ds DNA	/	<30 IU/ml	/

Ref.No. : 13/05 Date: 04-03-10

Patient Name :
 Age & Sex : 45 yrs/FEMALE
 Advised by Dr. : P.VENKATANARAYANA, M D
 Examination Required: RBS., E-S-R.
 Report :

- * RANDOM BLOOD SUGAR.....: 115 mg/dl
 RANDOM URINE SUGAR.....: NIL
 (normal. 70-160 mg/dl)
- * BLOOD POH E-S-R...: 26 mm at the end of 1st hour
 : 55 mm at the end of 11nd hour
 (normal. UP to 10 mm)

Patient Name : Gender: FEMALE
 Req. No. : 117 NZB Age : 45 YRS
 Ref. Dr. : P.VENKATA NARAYANA, M D Date : 04/03/10

ANTI RHEUMATOID FACTOR IgM

RESULT : POSITIVE (35.0 RU/ml)

METHOD : ELISA

INTERPRETATION:

NEGATIVE : Less than 20 RU/ml

POSITIVE : More than /Equal to 20 RU/ml

Prasanthi K
 DR. PRASANTHI K
 MICROBIOLOGIST

Verified by: *Qy*

After

Date : 23/03/2011

NAME : *

Ref by : Dr.P.Venkatanarayana

Rheumatoid Arthritis Factor (RA) Analyser Method

TEST NORMAL VALUE

NEGATIVE 2.62 IU/ml 0-10 IU / ml.

C. Reactive Proteins. (Analyser Method)

TEST NORMAL VALUE

POSITIVE 0.66 Mgs % 0.0 - 0.6 Mgs %

REPORT ON ERYTHROCYTIC SEDIMENTATION RATE

First half hour reading : 2 mm.

First hour reading : 5 mm.

Second hour reading : 11 mm.

Case of Fibroadenoma of Breast:



Homeopathy can offer solutions to Tumours as well. This set of before/ after reports show how multiple fibroadenomas of breast are cured with Homeopathic treatment.

Homeocare International offers treatment for fibroadenomas of breast, uterine fibroids, pcod, lipomas, Goitre and all such tumors and growths.

Before

PAT NAME: * 37 YRS F DATE: 13.11.2011

REF BY: DR. INDRA RAJA M.B.B.S., D.G.O., FAMIL.

MAMMOGRAM OF BOTH BREASTS

CLINICAL HISTORY : Discharge from nipple.

TECHNIQUE : Cranio - caudal (CC), Medio-lateral oblique (MLO) views of both breasts.

OBSERVATION:

- Both breasts are predominantly fatty in architecture with scattered areas of glandular parenchyma.
- Right breast shows multiple well defined, smooth margined rounded & oval shaped moderate density masses in all quadrants, with halo & without calcifications.
- In addition, smaller rounded lesions are seen in both breasts. No evidence of spiculated mass, architectural distortion, skin retraction or micro calcifications are seen in both breasts.
- Nipple, areolar region, skin and subcutaneous fat appear normal on both sides. Visualised parts of pectoralis muscles and fat planes appear normal.
- Small lymphnodes are seen in both axilla - normal finding.
- Ultrasound correlation shows evidence of well defined smooth margined hypo echotic solid masses of following size and position, with mobility and slipperiness.
 - 1.3 x 0.9 x 0.9 cms size in inner quadrant of right breast (3 o' clock position)
 - 1.8 x 1.3 x 0.7 cms size in outer quadrant of right breast (10 o' clock position)
 - 0.7 x 0.6 x 0.4 cms size in upper quadrant of right breast (12 o' clock position)
 - In addition, few other smaller simple cysts are seen in right breast.

IMPRESSION:

MULTIPLE FIBROADENOMAS OF RIGHT BREAST.

MULTIPLE SIMPLE CYSTS OF BOTH BREASTS.

NO OBVIOUS RADIOLOGICAL EVIDENCE OF MALIGNANCY SEEN IN BOTH BREASTS.

Kindly correlate clinically and histopathologically.

Thank you very much for your kind referral.

FILMS (4)

DR. P. S. S. SAMPAN, M.D. (PT), DNB (R), CONSULTANT RADIOLOGIST

After:

Name : * Date: 24.10.2012

Age : 38/F ID.No: 544

Ref. by : SELF

X-RAY - MAMMOGRAM OF BOTH BREASTS

The fibroglandular density is normal for age in both breasts.

Nipple and subareolar tissue are normal.

No retraction or skin thickening is seen.

Subcutaneous tissue and cooper's ligaments are normal.

No segmental rigidity is evident.

No evidence of any distortion of the tissues seen.

The pectoralis and retro mammary space appears normal.

No abnormal calcification is seen.

Axillary tail is normal.

No significant axillary lymph nodes are seen.

Impression:

No obvious abnormality is seen in the mammogram of both breasts at present.

Suggested clinical correlation.

DR. NISHA S. DOBH, M.D. (R), CONSULTANT RADIOLOGIST

Congenital Absences of Seminal vesicles:

A case of Young male presented with Infertility and on investigating was diagnosed with Azoospermia with Congenital Absence of Seminal Vesicles. After 10 months of Treatment at Homeocare International it is learnt from the reports that Small sized seminal vesicles appeared.

This case is only a grain of sand in desert of innumerable Homeopathic cures for incurable and chronic diseases.

Case of : Dr Rama Das

Before

REFERRED BY DR: RAJESH KISHA DATE: 24-12-2002
PATIENT'S NAME: *

TRANSRECTAL IMAGING OF PROSTATE WITH COLORFLOW MAPPING

Prostate imaged with 7 MHz transrectal probe with colorflow mapping.

Peripheral zone, central zone imaged.

Dist. urethral glands imaged:

prostatic echotexture normal.

No evidence of calcification.

Prostate measures: 3.1 x 2.5 x 2.9 cm.

Prostatic capsule intact.

Seminal vesicles and vas deferens could not be imaged.

* Agenesis.



SONOLOGIST: [Signature]

Name: [Redacted]
Age: 24 yrs.
Sex: Male
Ref by: Dr. Sanjay Sikha 18-Dec-02
18.12

Real Time Ultrasonography of the Abdomen is performed

- Liver:** Normal in size and contour. Parenchyma echotexture is normal. No intracystic biliary dilatation. Portal vein is normal. Cgd is normal.
 - Gall Bladder:** Normal in size. No evidence of calculi. Wall thickness is normal.
 - Spleen:** Normal in size and contour. Parenchyma echotexture is normal.
 - Pancreas:** Normal in size and contour. Parenchyma echotexture is normal. No calcifications. No peripancreatic fluid collection.
 - Kidneys:** Normal in size and contour. Parenchyma echotexture is normal. Corticomedullary differentiation is made out. No evidence of hydronephrosis. Rk = 93x42 mm & Lk = 82x44mm.
- Transrectal Area:**
- Urinary Bladder:** Full no calculi.
 - Prostate:** 31x27x23mm - Normal in size and echotexture. Seminal vesicles: Not visualized - 7 AMPLING: Dopplary stud. is also not visualized.
 - Aorta & VC:** are normal. No evidence of hypertension. No evidence of atherosclerosis. No mass lesion in the Aortic Aorta.
 - Seminal vesicle / seminal nodes:** Lt. sided vesicles.
 - Clinical history:** US findings are suggestive of Non visualization of seminal-vesicles - Congenital Absence.

After

Regd. No: HPC/0015/1114 File No: 6437/2017-14-00
Name: * Age Sex: 23 Years / Male
Regd. No: HPH/2257 Regd. Centre: Homeocare
Ref. Dr: KANDIAN

TRUS:

Transverse measure 34 mm.
Prostate is normal in size and echotexture.

Prostatic outline normal.

The differentiation between the peripheral and the central zone is made out, with no abnormality seen in the peripheral zone.

The central zone appears normal in size and echotexture.

Bilateral seminal vesicles are decreased in size.

Bilateral vas deferens are normal.

Bilateral ejaculated ducts are not dilated.

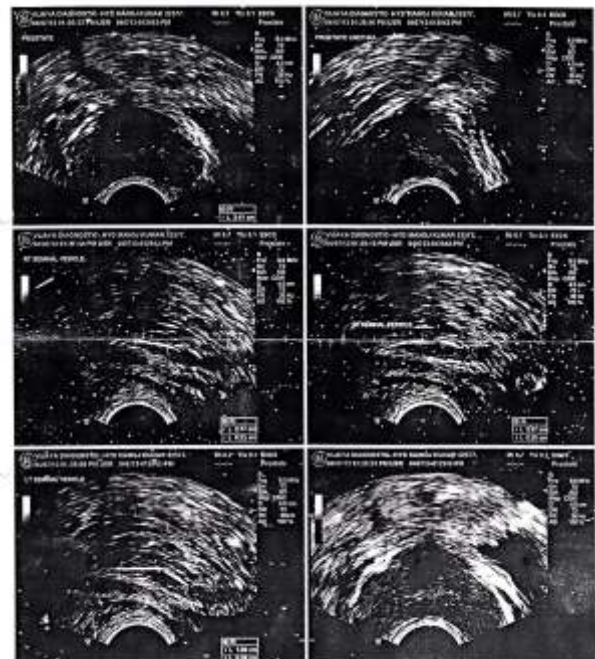
No evidence of cystic lesions in prostate.

Urinary bladder neck is normal.

DIPYRERSON:

- * SMALL SIZED BILATERAL SEMINAL VESICLES.
- * NORMAL STUDY OF PROSTATE.
- ADVISED MRI Craniocervical.

Dr. SK & PARVEEN, MD.,
CONSULTANT RADIOLOGIST



*Patient names hidden

Homeopathy **myths** and **facts**

HOMEOCARE
arogyā
 Be Healthy, Be Happy.

Myth: Homeopathic Medicines are slow to act and cannot be used in Acute Cases.

Fact: Most people take recourse in Homeopathy for chronic problems such as arthritis, allergies, asthma, psoriasis, vitiligo, hormone problems, infertility which take a longer time to be treated with any other system of medicine too. However in acute ailments like fever, diarrhoea, acute cold, cough etc., Homeopathic remedies act as fast as conventional medicines and can even act faster.

Myth: All Homeopathic medicines are the same sweet pills

Fact: Although all Homeopathic medicines look alike and taste alike, essentially they are not the same. The basic ingredients of Homeopathic medicines come from 3000 different sources that are mainly derived from plants and minerals. These various substances are extracted into various solvents to make liquid homeopathic medicines. For better palatability the liquid homeopathic medicines is poured into small sugar globules, which are highly porous and therefore absorptive. Although they may look alike, every Homeopathic remedy is different from one another.

Myth: Homeopathic medicines contain STEROIDS

Fact: Homeopathic medicines does not contain steroids. A good Homeopathic prescription which is geared towards stimulating and helping the body's defence system (Immune System) and works as an immuno modulator, there by giving fast relief in acute cases as well. Homeopathic remedies which are by and large derived from the plant kingdom. Homeopathic medicines does not contain steroids and does not give rise to any side effects like steroids.

Myth: Homeopathic and Allopathic medicines cannot be taken together

Fact: Homeopathy and allopathic medicines can be taken together and it is always advised to continue allopathic medicines if a patient is suffering from diseases such as Diabetes, HTN. Homeopathic medicines can be given even in conjunction with Radiotherapy and Chemotherapy in cancer cases.



www.homeocare.in

We

CARE FOR YOUR

Family's Health

- Spondylosis
- Disc Problems
- Knee Pains
- Rheumatoid Arthritis

- Diabetes
- Thyroid
- Infertility
- Sexual Problems

- PCOD
- Psoriasis
- Leucoderma
- Allergies



World's 1st
Constitutional
Homeopathy

OUR BRANCHES

Andhra Pradesh:

- **Hyderabad:**
 Begumpet
 Masabtank
 Miyapur
 Kukatpally
 Jubilee Hills
 Abids
 Dilsukhnagar
- Vijayawada
- Tirupathi
- Vizag
- Rajmundry
- Guntur
- Hanumakonda



Karnataka

- **Bengaluru :**
 Jayanagar
 Indira Nagar
 Malleshwaram
- Mangalore
- Hubli
- Davangere
- Bellary
- Mysore



Tamilnadu:

- **Chennai :**
 Tambaram
 Aminjikarai
 CIT Nagar
- Coimbatore
- Madhurai



Your family could also be complete & happy as theirs!



- PCOD • Abortions • Menstrual Problems • Tubal Blocks
- Hypo Thyroid • Diabetes • Sexual Problems
- Low Sperm Count • Premature Ejaculation • Erectile Dysfunction



HOMEOCARE **INTERNATIONAL** Pvt Ltd

LEADERS IN WORLD-CLASS HOMEOPATHY An ISO 9001-2008 Certified Clinic with German Accreditation

 www.facebook.com/homeocareint

Toll Free - 1800 102 2202

Andhra Pradesh: Hyderabad: Begumpet | Masabtank | Miyapur | Kukatpally | Jubilee Hills | Abids | Dilsukhnagar

Vijayawada | Tirupathi | Vizag | Rajmundry | Guntur | Hanumakonda

Karnataka Bengaluru : Jayanagar | Indira Nagar | Malleshwaram | Mangalore | Hubli | Davangere | Bellary | Mysore

Tamilnadu: Chennai : Tambaram | Aminjikarai | CIT Nagar | Coimbatore | Madhurai